

CASE REPORT

Management of Complicated Crown Fracture Using Fixed Sectional Orthodontic Extrusion Technique - A Case Report

Sk Mahboob Rahaman¹, Anuradha Mukherjee², Pintso Tshering Lepcha³, Soumik Kabasi⁴, Tanmoy Patra⁵

¹Assistant Professor, ²Professor and Head of the Department, Department of Conservative Dentistry & Endodontics; ³Assistant Professor, Department of Orthodontics; ⁴Assistant Professor, Department of Public Health Dentistry; ⁵Junior Resident, Department of Conservative Dentistry & Endodontics; North Bengal Dental College & Hospital, Sushrutanagar, Darjeeling -734012.

Corresponding Author: Dr. Sk Mahboob Rahaman, Assistant Professor, Dept. Of Conservative Dentistry & Endodontics, North Bengal Dental College & Hospital, Sushrutanagar, Darjeeling -734012. Email Id-rskmahboob@gmail.com

Abstract

Complicated crown fractures are one of the common situations encountered in the dental practice. It can often be challenging to the clinicians to deal such cases. The complexity of the cases will depend on the complexity of the injury, classification of the fractured tooth and aesthetic demand of the patient. The purpose of this article is to describe a case of complicated crown fracture which was managed successfully through segmental fixed orthodontic extrusion technique and its outcome is highlighted with consideration in this method of management. (2020, Vol. 04; Issue 01: Page 51 - 55)

Keywords: Tooth fracture, Gingival margin, Crown restoration, Orthodontic extrusion, Alveolar ridge, Maxillary anterior teeth.

Introduction

Crown-root fractures involve enamel, dentine and/or pulp and comprise up to 5% of all traumatic injuries (1). The management of fractured tooth is one of the common cases encountered in dental practice and out of all dental trauma fractured central incisor accounts for 71.42% in general. With the recent trend and attitude toward dental implants, extraction remains the common treatment modality. This, however, should be considered as the last option, and every attempt should be made to preserve and restore the natural tooth structure (2). Such treatment modalities involve a multi-disciplinary approach including endodontics, periodontal crown lengthening, and/or orthodontic extrusion followed by prosthetic rehabilitation. Periodontal crown lengthening involves the removal of supporting crestal alveolar bone

while orthodontic intervention forcibly extrudes the tooth. Both are attempts to expose sufficient coronal tooth structure for proper prosthetic restoration. Crown lengthening procedures may expose excess of root and in turn, may compromise esthetic results that can be avoided by the use of orthodontic extrusion (3-6).

The purpose of this paper is to review this multi-disciplinary treatment approach and to present a case of traumatized fracture maxillary central incisor tooth and its management maintaining the healthy periodontal tissue and alveolar bone.

Case report

A 46 year old male patient came to the department of Conservative Dentistry and Endodontics of North Bengal Dental College and Hospital with the chief complaint of dislodgement of crown in the upper

front tooth region following a traumatic injury 3 days back. On clinical examination tooth no 11 showed complicated crown fracture with residual cement and a porcelain fused to metal full coverage restoration in 21 (Fig 1A). The patients had generalized stain due to history of habitual smoking since last 5 year. Radiographic examination showed tooth no 11 and 21 were endodontically treated (Fig 1B).

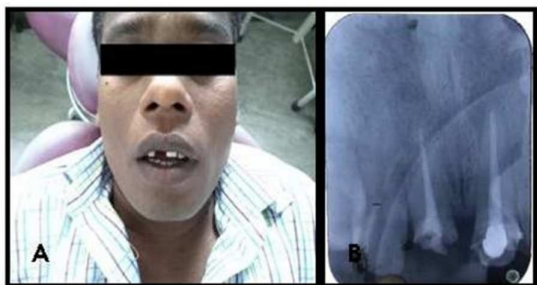

Figure 1: A- Fractured crown of 11, B- Radiograph of 11 and 21

Upon clinical evaluation tooth no 11 showed inadequate amount of ferrule with buried fracture margin below the gingival level (Fig 2A). There were two options regarding the management of the case either to do a surgical crown lengthening of the tooth but surgical crown lengthening of the tooth will cause apical displacement of the gingival zenith if done only on single tooth and total osteoplasty of the anterior segment will be large procedure and after all any surgical procedure carries its own complication. Another treatment is orthodontic extrusion of the tooth to gain adequate amount of ferrule. Both the treatment options were told to the patient and he wanted to avoid surgeries so orthodontic treatment was opted. A custom made extrusion hook fabricated using 22 gauge hard stainless steel wire with the help of adams plier and half round plier (Fig 2B).

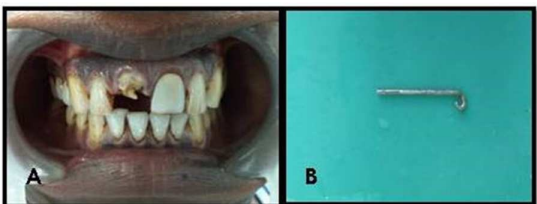


Figure 2: A- Intraoral view, B- Custom made extrusion hook

After residual cement removal a space was created by removing gutta percha from the root canal space (Fig 3A) and the extrusion hook was cemented with type 1 glass ionomer cement (Fuji 1 by GC America) (Fig 3B).

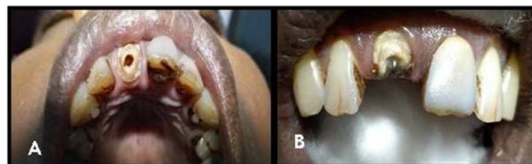

Figure 3: A- Space after removal of gutta percha in 11, B- Cementation of extrusion hook

MBT brackets were bonded on Tooth no 13,12,21,22,23. A 0.014 inch round Ni-Ti wire were reshaped and placed in the bracket slots and the extrusion hook and secured with elastomeric ligation (Fig 4).

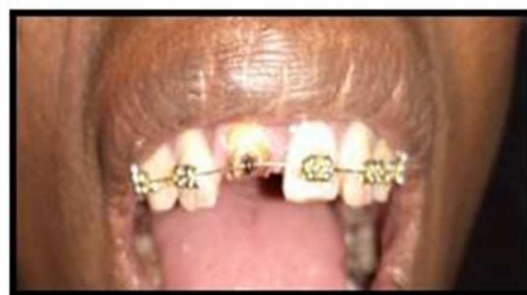

Figure 4: Placement of MBT bracket in upper anterior teeth

Patient is recalled after 1 week, 4th week and 6th week respectively. After 6th week adequate amount of ferrule was gained in the labial and palatal aspect. The brackets were debonded and crestal fibrectomy of tooth no 11 done to prevent the relapse. Post space was created after removing the extrusion hook and cement residues from the post space (Fig 5A). A cast post was fabricated (Fig 5B) and cemented in the prepared post space with type 1 glass ionomer cement (Fig 5C). Finally it was restored with full coverage porcelain fused to metal crown restoration (Fig 5D) and considerable amount of esthetic changes were seen after the completion of the treatment.

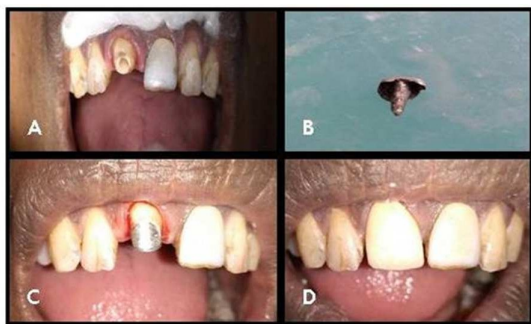


Figure 5: A- Post space in 11, B- Cast post, C- Cast post cementation, D- Porcelain fused to metal crown in 11

Discussion

Dental trauma, and ensuing fracture of the permanent anterior teeth, can be one of the most stressful situations in a dental practice, demanding a comprehensive treatment planning (7). Placing restorative margins within the biologic width frequently leads to gingival inflammation, clinical attachment loss, and bone loss. This is thought to be due to the destructive inflammatory response to microbial plaque located at such depths. Thus, it is important to maintain health of periodontium during restoration in sub-gingival areas. Ingber et al. suggested that a minimum distance of 3 mm is required from the restorative margin to the alveolar crest to permit adequate healing and restoration of the tooth that is biologically acceptable (8). Movement of a tooth by extrusion involves applying tractional forces in all regions of the periodontal ligament to stimulate marginal apposition of crestal bone. Because the gingival tissue is attached to the root by connective tissue, the gingiva follows the vertical movement of the root during the extrusion process. Similarly, the alveolus is attached to the root by the periodontal ligament and is in turn pulled along by the movement of the root (9). Extrusion is easiest of all orthodontic movements because it closely resembles natural tooth eruption (10). If the fracture line is positioned both below alveolar bone and gingival free margin, and, if the length of the root segment is sufficient enough to support a coronal restoration, then the root can be endodontically treated and, afterwards, orthodontically extruded to elevate the fracture plane

above the gingival margin. These procedures enable more favorable prosthodontic coronal restoration by securing its good sealing and esthetics, and, moreover, preserving a good periodontal tissue health

(11). In normal course of events, bone and gingival movements are produced under low-intensity extrusive forces. When stronger traction forces are exerted, as in rapid extrusion, coronal migration of the tissues supporting the tooth is less pronounced because the rapid movement exceeds their capacity for physiologic adaptation (12). Thus, rapid extrusion is necessary to prevent movement of the gingival collar and alveolar bone with the elevated tooth. Forces of 15 g for the fine root of a lower incisor and 60 g for a molar are sufficient for slow extrusion. Some authors recommend that the maximum force for a slow movement should not exceed 30 g, whereas rapid extrusions are accomplished with forces higher than 50 g (13- 15).

When one tooth has luxated or fractured, the adjacent tooth might have also suffered some injury, hence anchorage of 2-3 healthy teeth should be taken (16). Orthodontic extrusion forces coronal migration of the root and increases the bone ridge as well as the quantity of attached gingiva, in particular when weak to moderate forces are applied. The amount of attached gingiva is increased through eversion of the sulcular epithelium, appearing first as immature non-keratinized tissue (known as "red patch") and then as keratinized tissue; the process of keratinization requires 28 to 42 days (17). After coronal movement of the periodontal attachment has occurred, minor surgical correction may be necessary (14). Moreover, when the tooth is moved to a new position, cervical periodontal fibers are stretched and may become a cause of relapse. Thus, such case might require surgical fibrotomy (18, 19). For the present case, the fracture line on palatal side was below the level of gingiva. Thus, did not provide sufficient coronal tooth structure and adequate biological width for a proper coronal restoration. This left us with the option of either extraction followed by implant or retaining the root fragment with subsequent rehabilitation. All the aspects were discussed

with the patient. The option of implant was out-rightly rejected considering the high cost involved and psychological taboo of extraction. The patient was given the other option of retaining the natural root by endodontic treatment followed either by periodontal treatment or forced eruption. The patient agreed for the latter as it was more physiological, no need for any surgical procedure and most importantly, cost-effective.

The amount of extrusion estimated to necessity, considering the 'biologic width' was approximately 4 mm (20, 21). The root length of the fractured incisor allowed the tooth to undergo the necessary amount of extrusion and still retain a crown-root ratio of approximately 1:1. This ratio is favorable for maintaining periodontal support (22). In this case, the root length of fractured incisor was enough for orthodontic extrusion.

Conclusion

A multidisciplinary approach can help save teeth which would otherwise be indicated for extraction. In this clinical report, a treatment modality for forced eruption therapy that minimizes treatment time and increases ease of use was described. The use of this technique for forced eruption may help the general dentist to have a better esthetic result and better patient appreciation.

The key to success are the right indications for the treatment and the dedication of the dentist to reassure and motivate the patient throughout the whole course of treatment, as well as institute a strict and regular recall regimen to guarantee the long term prognosis.

References

1. Estanga AA, Castelo-Baz P, Bello-Castro A, Ramos-Barbosa I, Martin-Biedma B, Blanco-Carrion J. Management of a crown-root fracture: A novel technique with interdisciplinary approach. *J Clin Exp Dent*, 2018; 10(6): e620-623.
2. Patil SS, Panicker A, Hindlekar A, Srinidhi SR, Dhupal A, Vhora K. Forced Orthodontic Extrusion for Anterior Traumatized Teeth by a Simplistic Approach. *J Dent Allied Sci*, 2014; 3: 111-113.
3. Delivanis P, Delivanis H, Kuftinec MM. Endodontic-orthodontic management of fractured anterior teeth. *J Am Dent Assoc*, 1978; 97: 483-485.
4. Johnson RH. Lengthening clinical crowns. *J Am Dent Assoc*, 1990; 121: 473-476.
5. Ivey DW, Calhoun RL, Kemp WB, Dorfman HS, Wheless JE. Orthodontic extrusion: Its use in restorative dentistry. *J Prosthet Dent*, 1980; 43: 401-407.
6. Fournier A. Orthodontic management of subgingivally fractured teeth. *J Clin Orthod*, 1981; 15: 502-503.
7. Rajan RR, Muddappa SC, Rajendran P, Nair AS. Management of Cervically Fractured Central Incisors: A Multidisciplinary Approach. *The Open Dentistry Journal*, 2018; 12: 238-245.
8. Mittal R, Gupta S, Singla A, Gupta A. Managing sub-lingival fracture by multi-disciplinary approach: Endodontics-forced orthodontic extrusion and prosthetic rehabilitation. *Saudi Endod J*, 2013; 3(2): 82-86.
9. Bach N, Baylard JF, Voyer R. Orthodontic extrusion: Periodontal Considerations and Applications. *J Can Dent Assoc*, 2004; 70: 775-780.
10. Biggerstaff RH, Sinks JH, Carazola JL. Orthodontic extrusion and biologic width realignment procedures: Methods for reclaiming non-restorable teeth. *J Am Dent Assoc*, 1986; 112: 345-348.
11. Bielicka B, Bartkowiak M, Urban E, Tomasz M. Holistic approach in the management of subgingivally fractured pre-molar tooth: Case Report *Dent Med Prob*, 2008; 45: 211-214.
12. Sabri R. L'allongement coronaire par l'égression orthodontique. Principes et techniques. *J Parodontol*, 1989; 8: 197-204.
13. Minsk L. Orthodontic tooth extrusion as an adjunct to periodontal therapy. *Compend Contin Educ Dent*, 2000; 21: 768-770.
14. Reitan K. Clinical and histological observations on tooth movement during and after orthodontic treatment. *Am J Orthod*, 1967; 53: 721-745.
15. Bondemark L, Kurol J, Hallonsten AL, Andreason JO. Attractive magnets for

orthodontic extrusion of crown-root fractured teeth. *Am J Orthod Dentofacial Orthop*, 1997; 112: 187-193.

16. Chaushu S, Shapira J, Heling I, Becker A. Emergency orthodontic treatment after the traumatic intrusive luxation of maxillary incisors. *Am J Orthod Dentofacial Orthop*, 2004; 126: 162-172.

17. Andreasen FM, Andreasen JO, Cvek M. Root fractures: In: Andreasen FM, Andreasen JO, editors. *Textbook and color atlas of traumatic injuries to teeth*. Copenhagen: Blackwell Publishing Ltd; 2007; p. 337-71

18. Arhun N, Arman A, Ungor M, Erkut S. A conservative multidisciplinary approach for improved aesthetic results with traumatized anterior teeth. *Br Dent J*, 2006; 201: 509-512.

19. Ji J, Luo XP, Lu W, Shi YJ, Wu L, Shu CJ. Esthetics restoration after rapid orthodontic extrusion of subgingivally fractured incisor: A case report. *Hua Xi Kou Qiang Yi Xue Za Zhi (West China Journal of Stomatology)*, 2007; 25(2): 206-207.

20. Ingber JS, Rose LF, Coslet JG. The 'biologic width'- a concept in periodontics and restorative dentistry. *Alpha Omegan*, 1977; 10: 62-65.

21. Stern N, Becker A. Force eruption: biological and clinical considerations. *J Oral Rehabil*, 1980; 7: 395-402.

22. Andreasen JO. *Traumatic Injuries of the Teeth*, 2nd edn. Copenhagen: Munsgaard, 1981, p. 112.