

CASE REPORT

Bilateral Transposition of Canine-Premolar: A Case Report

Ruma Mandal¹, Ravindra D. Rekhade², Sankha Biswas³, Vivek Agarwal³, Debapratim Jana⁴, Archak Chakraborty¹

¹Post Graduate Student, ²Professor & Head of the Department, ³Professor, ⁴Senior Lecturer, Department of Orthodontics and Dentofacial Orthopaedics, Haldia Institute of Dental Sciences & Research, West Bengal.

Corresponding Author: Dr. Ruma Mandal, Post Graduate Student, Department of Orthodontics and Dentofacial Orthopaedics, Haldia Institute of Dental Sciences & Research, West Bengal. Email id: ruma.mandal17@gmail.com.

Abstract

Maxillary canine and 1st premolar transposition is a developmental disturbance of tooth sequence characterized by interchange of positions of maxillary canine and 1st premolar. Early diagnosis and interception of transposition can simplify the orthodontic treatment. This is a case report of the management of a developing maxillary canine and 1st premolar transposition by Non-extraction therapy. Natural tooth sequence was attained and symmetric and functional Class I molar relation was achieved. (2020, Vol. 04; Issue 01: Page 65 – 69)

Keywords: Tooth transposition, Ectopic eruption.

Introduction

Tooth transposition is defined as the interchange of position of two adjacent teeth – particularly of the roots. “Ectopic Eruption” is the development and/or eruption of a tooth occurs in a position normally occupied by a non-adjacent tooth. Ectopic eruption of varying degrees has been labelled as pseudo transpositions by some authors. Ectopic eruption is a broad category referring to any abnormal or aberrant eruptive path taken by tooth (1). Tooth transpositions, therefore, must be properly considered as a subdivision of ectopic eruption (2).

Tooth transpositions can be complete or incomplete. A complete transposition is when the positions of the crown and root of two adjoining teeth get interchanged in the dental arch. An incomplete transposition is where the crowns are transposed but the roots

retain in their normal positions (3). Tooth transposition is usually associated with other dental anomalies, such as hypodontia, peg-shaped teeth, severe rotations, retention of deciduous teeth, dilacerations, and malformations of other teeth (4). Canine transposition can affect either of the dental arches of both males and females. However the incidence among females has been more frequently reported (2). Transposition commonly occurs in the Maxilla. Unilateral canine transposition has been reported to occur more frequently (79%). The left side is more commonly affected (69%) than bilateral. Bilateral transposition has been reported in 5% of the cases (5).

Classification

Peck and Peck reviewed a large number of case reports of tooth transpositions in the maxillary arch. They proposed a

classification based on anatomical factors among 201 individuals in a study sample. The five maxillary transposition types were named and abbreviated according to the teeth involved: (6, 7)

- Canine- first premolar (Mx. C. P1)- 71%
- Canine-lateral incisor (Mx. C. I2)- 20%
- Canine to first molar site (Mx. C to M1)- 4%
- Lateral incisor- central incisor (Mx.I2. I1)- 3%
- Canine to central incisor site (Mx. C to I1)- 2%

Etiology

S. and L. Peck reported that transpositions have a genetic origin, although a variety of local factors can contribute to their development. Other possible causes of transposition include: (2, 8-11)

1. The interchange of positions of the developing tooth buds at an early stage of dental development.
2. An overretained deciduous canine could be the primary cause of the displacement and migration of the erupting permanent canine from its normal path of eruption.
3. Bone pathology, such as cyst formation, may also cause displacement and transposition of the tooth.
4. Dentofacial trauma in the deciduous dentition and subsequent permanent tooth drift.

Transposition is a rare developmental anomaly of tooth. Early diagnosis of a developing transposition is extremely important and has a great influence on prognosis of Orthodontic treatment. A transposition is usually first detected clinically. A conventional orthopantomogram can be useful if the patient is between 6 and 8 years of age. When the transposition is detected early, the complete development and expression of this anomaly can be prevented by interceptive procedures. The modalities of treatment could include extraction of deciduous teeth and guiding the eruption of the permanent teeth. When

transposition is complete, the treatment to completely reposition the involved teeth is complicated. It may cause damage to the supporting tissues. Thus, alignment of these teeth in their transposed positions is usually preferred. Extraction of a permanent tooth, usually the premolar, is required when teeth affected by transposition present caries or poor periodontal support or when there is a severe tooth-size discrepancy (2).

Case report

A female patient aged 13 years reported to the Department of Orthodontics and Dentofacial Orthopaedics at Haldia Institute of Dental Sciences. Her chief complaint was irregularity of the teeth in upper and lower jaws. Extraoral examination (Fig 1) revealed mesocephalic head, mesoprosopic facial form and no facial asymmetry. The facial profile was straight. Facial proportions were within normal range. The intraoral examination showed the presence of all permanent teeth except third molars in all the quadrants. A retained maxillary left deciduous canine was present. Further examination revealed an Angle's Class I molar relationship on both sides, overjet of 1.5 mm and overbite of 3 mm (Fig 1). The maxillary right and left canines were erupting buccally.

Panoramic radiographic examination revealed the maxillary canines were erupting between the two maxillary premolars on both the right and left sides. There was complete transposition of maxillary canine with maxillary first premolar bilaterally. The roots of maxillary first and second premolars were diverging apically. Cephalometric analysis shows skeletal class III base with average growth pattern (Fig 2). Pre-treatment study casts were made (Fig 3).

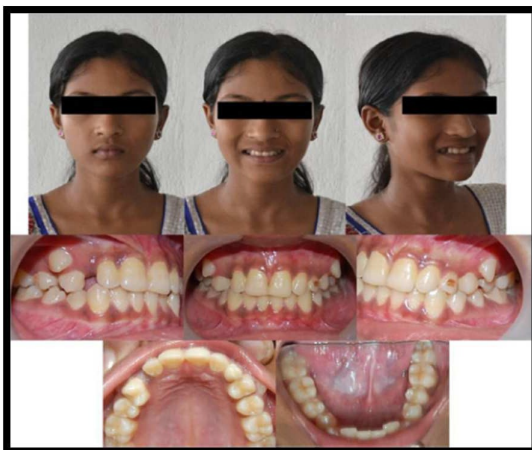

Fig 1: Extra oral and Intra oral Photographs

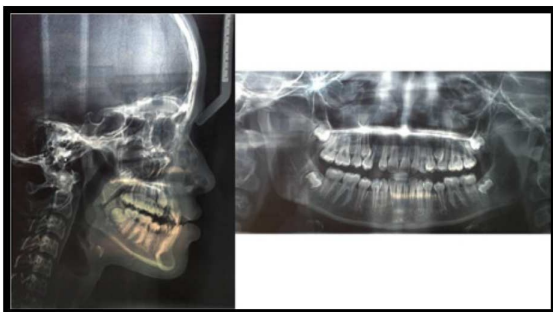


Fig 2: Orthopantomograph and Cephalometry

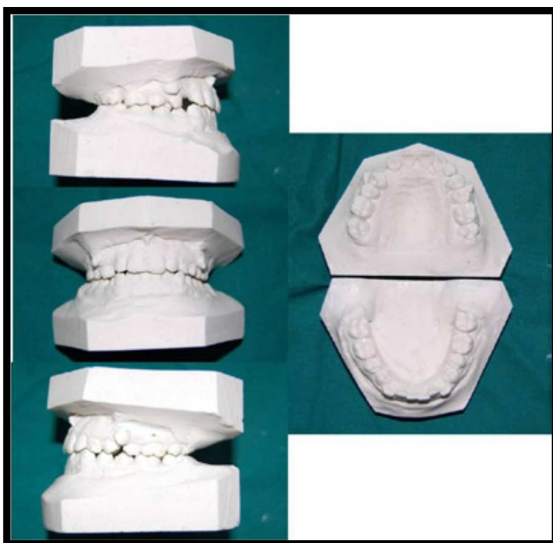

Fig 3: Pre-treatment dental casts

Treatment Objectives

The treatment objectives include:

1. Maintenance of class I molar relationship.
2. Maintenance of ideal overbite and overjet
3. Aligning the transposed maxillary canines and first premolars.
4. Maintenance of facial balance.

Treatment Options

1. Correcting the order of transposed teeth
2. Maintaining the order of transposed teeth.
3. Extraction of one transposed teeth

Treatment Plan

An attempt to correct transposed teeth in the permanent dentition was not attempted due to the potential risk of damaging the teeth or supporting structures. Therefore, alignment of the involved teeth in their transposed position was done. The treatment plan was to maintain the order of transposition. The retained left deciduous canine was extracted in the initial stage of treatment. A 0.22" slot (MBT - 0.022 × 0.028) pre-adjusted edgewise prescription was used.

Treatment Mechanics

The orthodontic treatment was initiated by banding maxillary first permanent molars in all quadrants and bonding of brackets in upper and lower arches except maxillary canines. Alignment was carried upto 0.017"×0.025 niti arch wire progressively. Once the initial alignment was completed, 0.017× 0.025 stainless steel arch wires were placed both in the upper and the lower arch. Open coil springs were placed between first and second premolars to gain space for the buccally transposed canine. The maxillary canines were bonded and aligned to within the arch. In final phase of treatment, 0.19×0.025" stainless steel arch wire were used. Panoramic radiograph

was taken to check for the root parallelism.

Treatment result

The maxillary canines and first premolars were successfully aligned maintaining the order of transposition. Angle's class I molar relationship with ideal overbite and overjet was maintained. Maximum intercuspation was obtained (Fig 4, Fig 5, Fig 6).

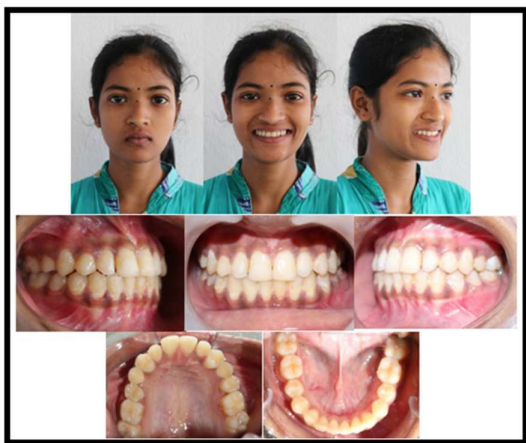

Fig 4: Post-treatment Intra and Extra oral photographs

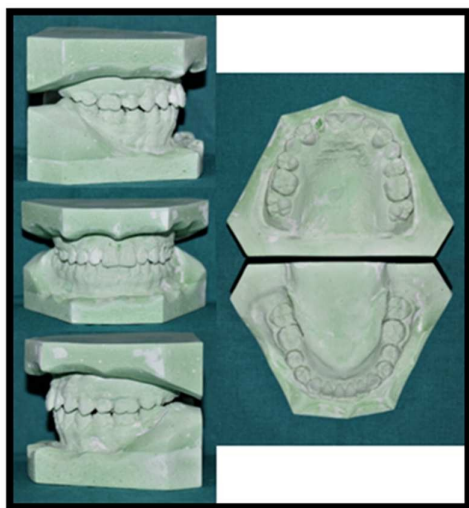


Fig 5: Post-treatment Dental Casts

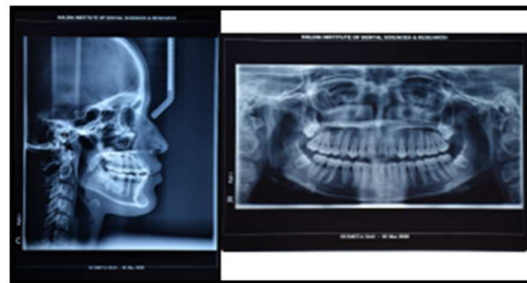


Fig 6: Post-treatment radiographs

Discussion

According to Peck and Peck, the best time for the intervention of transposition is when the maxillary canine is undescended with its cusp tip positioned superiorly relative to the root of the first premolar (6). It was decided not to intervene and correct the transposition in this patient as the maxillary canines had already erupted buccally. The treatment alternatives were to correct the bilateral transposition with or without the extraction of premolars. The correction of transposition was possible by extraction of four first premolars. This treatment plan was also faster and simpler in terms of mechanics. But this treatment plan was not indicated in this patient as the profile of the patient was straight. The other treatment option was either to correct the transposition or aligning the teeth in a transposed order. The attempt to correct transposition of teeth would require prolonged orthodontic treatment and patient compliance. It may cause damage to the surrounding tissue and resorption of the roots due to root interference (2, 12). Treatment plan with retaining the teeth in transposed order was thought to be a practical approach as it requires less treatment time. Esthetics and function would not be compromised much with a transposed finish as the two teeth had resemblance and the lingual cusp of the first premolar could be reduced in the event of functional interference. It was decided not to correct the transposition and aligning the teeth in transposed position after considering the case difficulty, timing, risks, esthetics, function,

stability, biological cost or damage. The disadvantages of maintaining the transposed positions include occussal interference during mandibular lateral movements. The anterior esthetics may be compromised as the gingival margin of the first premolar is relatively lower than canine. This may require reduction of the palatal cusps of transposed first premolar and gingival recontouring. The patient was informed about the possibilities in order to maintain the teeth in transposed position. The patient refused to undergo any gingival recontouring procedure and satisfied with the alignment of maxillary anterior teeth.

Conclusion

Early diagnosis of any transposition can help in correction with favourable prognosis and less chance of injuries to the periodontal tissues. The mechanics to correct transposition are complex, treatment time is long, and dental tissues can be damaged. The patient's compliance, esthetics, function, caries risk and age should all be considered when deciding whether treatment of a transposition should involve tooth extractions, tooth alignment in the transposed order, or orthodontic correction of the transposition.

References

1. Peck L, Peck S, Attia Y. Maxillary canine-first premolar transposition, associated dental anomalies and genetic basis. *Angle Orthod*, 1993; 63: 99-109.
2. Filho LC, Cardoso MA, An TL, Bertoz FA. Maxillary Canine—First Premolar Transposition: Restoring Normal Tooth Order With Segmented Mechanics. *Angle Orthodontist*, 2007; 77(1): 167-175.
3. Shapira Y, Kuftinec MM. Tooth transpositions - a review of the literature and treatment considerations. *Angle Orthod*, 1989; 59(4): 271-276.
4. Shapira Y, Kuftinec MM, Stom D. Maxillary canine-lateral incisor transposition- Orthodontic management. *Am J Orthod Dentofac Orthop*, 1989; 95: 439-444.
5. Francisco Ajalmar Maia. Orthodontic Correction of a Transposed Maxillary Canine and Lateral Incisor. *Angle Orthod*, 2000; 70: 339-348.
6. Peck S, Peck L. Classification of maxillary tooth transpositions. *Am J Orthod Dentofacial Orthop*, 1995; 107: 505-517.
7. Laurent D, Valerie O, Manon S, Pierre C. Transpositions of maxillary canines: Periodontal aspects and orthodontic therapy. *J Dentofacial Anom Orthod*, 2010; 13: 133-150.
8. Joshi MR, Bhatt NA. Canine transposition. *Oral Surg*, 1971; 31: 49-54.
9. Y.C. Tseng, H.P. Chang, T.M. Chou. Canine Transposition. *Kaohsiung J Med Sci*, 2005; 21: 441-447.
10. Nishimura K, Nakao K, Aoki T, Fuyamada M, Saito K, Goto S. Orthodontic correction of a transposed maxillary canine and first premolar in the permanent dentition. *Am J Orthod Dentofacial Orthop*, 2012; 142(4): 524-533.
11. Tripathi S, Singh RD, Singh SV, Arya D. Maxillary canine transposition: A literature review with case report. *J Oral Biol Craniofac Res*, 2014; 4(2): 155-158.
12. Johnny Liaw, John Lin and Greg Huang, The Applications of TADs in Canine Transpositions, *Seminars in orthodontics*, doi:10.1053/j.sodo.2018.01.013