

CASE REPORT

Clinical Management of Horizontal Mid-Root Fracture In Maxillary Lateral Incisor – A Case Report

Anil Dhingra¹, Anshdeep Singh², Shalini Sharma³

¹Professor and Head of the Department, ²Reader, ³Post Graduate Student, Department of Conservative Dentistry and Endodontics, Seema Dental College and Hospital, Rishikesh, Virbhadra Road, Uttrakhand, 249203, India.

Corresponding Author: Prof. (Dr.) Anil Dhingra, Professor and Head of the Department, Department of Conservative Dentistry and Endodontics, Seema Dental College and Hospital, Rishikesh, Virbhadra Road, Uttrakhand, 249203, India. Email Id- anildhingra5000@yahoo.co.in

Abstract

The treatment of traumatic dental injuries is an important aspect of clinical dentistry. Root fracture is a type of traumatic dental injury and is defined as fracture involving cementum, dentin and pulp. The diagnosis of root fracture is determined by clinical and radiographic examination. Horizontal root fractures occur primarily in the anterior portion of the mouth, especially in the maxilla and are often caused by physical trauma to the face. In this article, we present a case of horizontal root fracture management of maxillary lateral incisor. (2019, Vol. 03; Issue 01: Page 33 - 35)

Key words: Injury, Root fracture, Glass fiber post.

Introduction

The treatment of traumatic dental injuries is an important aspect of clinical dentistry. Root fractures are a type of traumatic dental injury and are defined as fractures involving cementum, dentin and pulp (1). Root fracture trauma occurs at approximately 1% frequency within the permanent dentition and has a poor prognosis if not managed appropriately (2). Horizontal root fractures occur primarily in the anterior portion of the mouth, especially in the maxilla and are often caused by physical trauma to the face (3). The diagnosis of root fractures is determined by clinical and radiographic examination (4, 5). Pathological complications of horizontal

fracture include pulp necrosis, root canal obliteration, external and internal inflammatory surface resorption, inflammation around the fracture, periapical inflammation. The space between the root fragments and the vitality of the periodontal ligament and pulp can also affect the treatment of a fracture, as well as the type of healing (6). The common types of healing include: healing with interposition of hard tissue, healing with interposition of bone and soft tissue between the fragments, healing with interposition of soft tissue, or no healing (7). The present case report describes the management of horizontal fracture at mid-

dle third of the maxillary right lateral inci- sor through non-surgical approach.

Case Report

A 25- year -old male patient reported to the department with chief complaint of broken teeth in the upper front tooth re- gion of the jaw having a history of trau- matic fall 1 month ago. Clinical examina- tion revealed Ellis class IV fracture and as- sociated grayish black discoloration in re- lation to #11 and class II fracture in rela- tion to #12 without mobility. There was no tenderness to percussion and negative re- sponse to pulp sensitivity tests. There was horizontal fracture in the middle third re- gion of root in relation to #12 (Fig 1). The confirmatory diagnosis was Asymptomatic Apical Periodontitis for #12. A single visit root canal therapy was planned for tooth #12. After rubber dam isolation, access cavity preparation was done and working length was determined (Fig 2A & B). Step- back technique for shaping was followed accompanied by passive irrigation with 3% NaOCl, normal saline, 17% EDTA and fi- nal irrigation with 2% chlorhexidine. Cal- cium hydroxide intracanal medicament was placed for two weeks and access cav- ity sealed with Cavit. On recall after 2 weeks obturation was done with gutta per- cha and AH Plus sealer (Fig 3). Post space was prepared for tooth #12 beyond frac- ture line with peeso-reamers no.2 followed by placement of glass fiber post luted with dual cure resin cement [Paracore, coltene] (Fig 4).

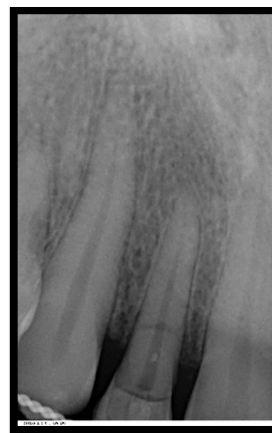


Fig 1: Preoperative radiograph

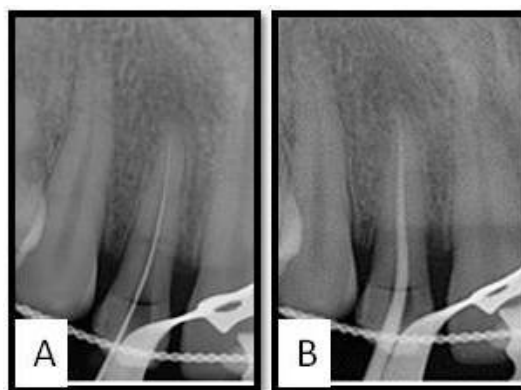


Fig 2: A- Working length determination, B- Master cone selection.

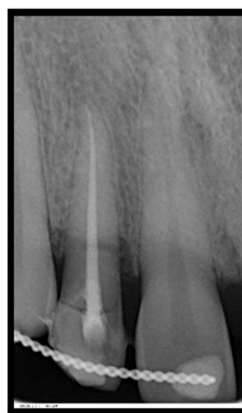

Fig 3: Obturation of #12

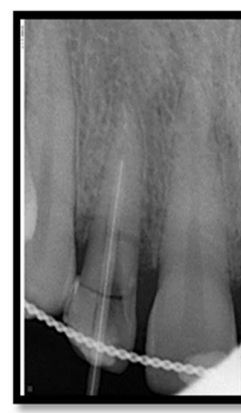

Fig 4: Fiber post luted with dual cure resin cement.

Discussion

Glass fiber post was used for intra radicular anchorage as it is aesthetic, has high fatigue strength, high tensile strength and modulus of elasticity similar to that of dentin (10). Horizontal fracture repair occurred as hard tissue forming cells originate from the intact periodontal ligament (11, 12).

Conclusion

A permanent tooth with horizontal root fracture that was endodontically treated and a glass fiber post fabricated for intraradicular anchorage presents a good prognosis preserving aesthetic and psychological integrity of the patient and hence quality of life. Clinical and radiographic follow up is essential for success of treatment for a tooth with horizontal root fracture.

References

1. Andreasen FM, Andreasen JO. Resorption and mineralization processes following root fracture of permanent incisors. *Endod Dent Traumatol*, 1988; 4(5): 202-214.
2. Brandini DA, Poi WR, Panzarini SR, Sonoda CK, de Castro JC, Luvizuto ER, Leal CR. Integrated treatment to resolve a horizontal root fracture. *Dent Traumatol*, 2009; 25:e16-20.
3. Bender IB, Freedland JB. Clinical considerations in the diagnosis and treatment of intra-alveolar root fractures. *J Am Dent Assoc*, 1983; 107(4): 595-600.
4. Polat-Ozsoy O, Gulsahi K, Veziroglu F. Treatment of horizontal root-fractured maxillary incisors--a case report. *Dent Traumatol*, 2008; 24(6): e91-95.
5. Belobrov I, Weis MV, Parashos P. Conservative treatment of a cervical horizontal root fracture and a complicated crown fracture: a case report. *Aust Dent J*, 2008; 53(3): 260-264.
6. Andreasen FM, Andreasen JO, Bayer T. Prognosis of root fractures: prediction of healing modalities. *Endod Dent Traumatol*, 1989; 5: 11-22.
7. Cvek M, Mejare I, Andreasen JO. Healing and prognosis of teeth with intra-alveolar fractures involving the cervical part of the root. *Dent Traumatol*, 2002; 18(2): 57-65.
8. Gabris K, Tarjan I, Rozsa N. Dental trauma in children presenting for treatment at the department of dentistry for children and orthodontics, Budapest, 1985-1999. *Dent traumatol*, 2001; 17: 103-108.
9. Oztan MD, Sonat B. repair of untreated horizontal root fracture: A case report. *Dent Traumatol*, 2001; 17: 240-243.
10. Aquaviva SF, Shetty S. Factors determining post selection: A literature review. *J Prosthet*, 2003; 90: 556-562.
11. Andreasen JO, Hjorting-Hansen E. Intra-alveolar root fractures: radiographic and histologic study of 50 cases. *J Oral surg*, 1967; 25: 414-426.
12. Andreasen JO, Andreasen FM, Andersson L. *Textbook and Color Atlas of Traumatic Injuries to the Teeth*. 5th Edition, Wiley-Blackwell; 2007: 337-371.