

CASE REPORT

UNUSUAL CASES OF UNILATERAL TRANSMIGRATION OF IMPACTED MANDIBULAR CANINE

Dr. Anuj Mishra¹, Dr. Debanti Giri²

¹Senior lecturer, Dept of Oral Medicine and Radiology, Sardar Patel Post Graduate Institute of Dental & Medical Sciences, Raibareilly Road, Lucknow, Uttar Pradesh. ²Clinical Tutor cum Demonstrator, Dept of Oral Medicine and Radiology, Dr. R. Ahmed Dental College & Hospital, Kolkata.

Corresponding Author: Anuj Mishra, Dept of Oral Medicine and Radiology, Sardar Patel Post Graduate Institute of Dental & Medical Sciences, Raibareilly Road, Lucknow, Uttar Pradesh. Email id: oralradiologist12@gmail.com.

Abstract

Failure of eruption of the mandibular canine is unusual. Transmigration of a mandibular canine across the midline is a rare condition with obscure etiology. The mandibular permanent canine is the only tooth in the dental arch reported to migrate across the midline, but it usually remains within the same side of the arch. The treatment of transmigrated mandibular canine demands clinical expertise. Whether the tooth is symptomatic or not the treatment options vary according to the needs of the individual. (2018, Vol. 02; Issue 01: Page 26 - 30)

Keywords: Impacted canine, Transmigration, Mandibular, Panoramic radiograph.

Introduction

Migration of teeth is a rare anomaly; pre-eruptive migration of a tooth across the midline is called Transmigration (1). Numerous theories have been put forth but none of which do accurately define the cause (2). The etiology is not known for its occurrence, but there are many and varied etiological factors that may be involved, such as retention or premature loss of a primary tooth, ectopic growth of the tooth bud, inadequate eruption space and excessive length of crown (3). Impaction of canine is more prevalent in the maxilla

than in the mandible, transmigration of canine is more frequent in the mandible. The prevalence of mandibular canine impaction, in general population, ranges from 0.35% to 0.44% (4). The less common finding is the migration of a mandibular canine from its normal position to the contralateral side, crossing the midline. This phenomenon is known as transmigration, and it occurs almost exclusively with mandibular canines (5). Tarsitano (1971) et al defined transmigration as a phenomenon in which an unerupted mandibular canine

migrates and crosses the midline (6). Tar- sitano's definition was further modified by Javid (1985), adding that at least one half or more of the length of the tooth is re- quired to cross the midline. Auluck (2006) et al. suggested that the actual distance of canine migration across the mandibular midline is less important than the tendency of the canine to cross the midline (7). Joshi (2001) felt that the tendency of a canine to cross the barrier of the mandib- ular midline suture is a more important

parameter than the distance of migration after crossing the midline (5,8).

Mupparapu has proposed a classification for both unilaterally and bilaterally trans- migrating mandibular canines (Fig 1 & 2). Moreover, the transmigration of tooth at the time of examination is a determining factor in the distance travelled (1). The cases of unilateral canine transmigration and the patterns of transmigration were studied and 2 cases of transmigration are presented in this context.

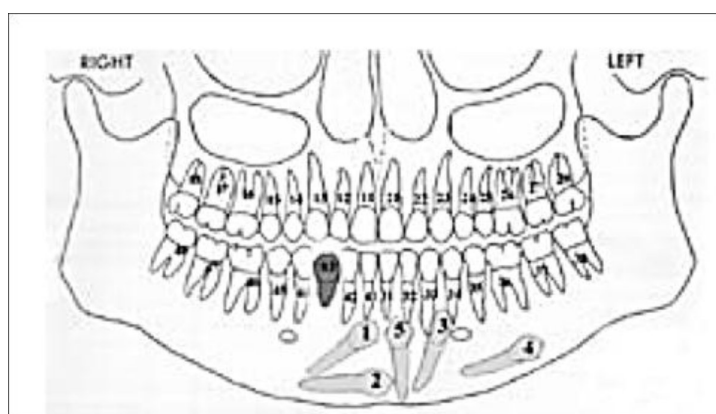


Fig 1: Diagrammatic representation depicting the five distinct patterns of unilateral transmigration of mandibular canines by Mupparapu

Case reports

Case 1

A 26 year old woman visited to department of Oral Medicine & Radiology, with the chief complaint of mobile teeth in lower front region of the jaw since 1 week. In- traoral examination revealed bilaterally retained deciduous mandibular canines

were observed and clinically permanent canines were missing in the lower jaw. A panoramic radiograph was taken, which revealed bilaterally impacted mandibular canines were lying vertically in midline just below the apices of mandibular inci- sors with no resorption on the deciduous canine (Fig 3).

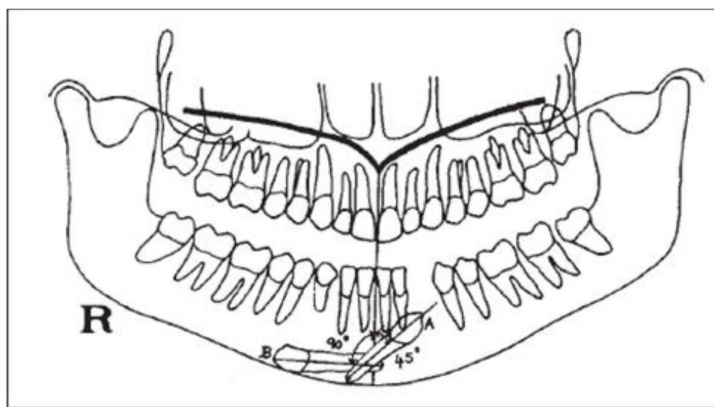


Fig 2: Diagrammatic representation of transmigrating mandibular canines axially inclined at 45- and 90-degree angulations from the midsagittal plane by Mupparappu

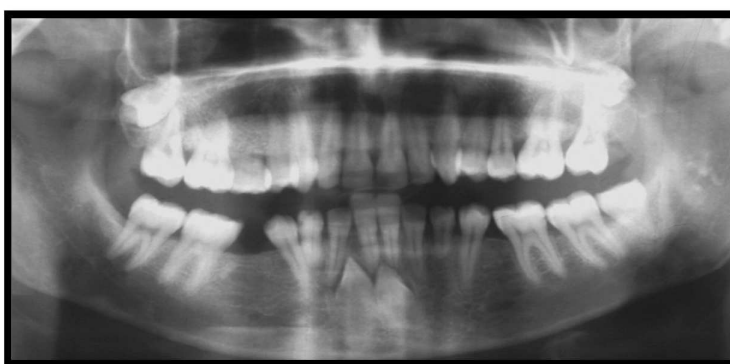

Fig 3: Type I subtype A. Bilaterally impacted canines located below the apices of the incisors in vertical position. Canine inclination is close to 45 degrees from midsagittal plane.

Case 2

A 17-year-old male reported to department of Oral Medicine & Radiology, with a chief complaint of irregular tooth in lower front tooth region. Medical history was non contributory. Clinical examination revealed all permanent teeth were present

except both mandibular canines. The panoramic radiograph revealed that both the mandibular canine was impacted and transmigrated to the midline and lying beneath the apices of mandibular anterior teeth; both the canines were “Kissing” each other with labial surface (Fig 4).

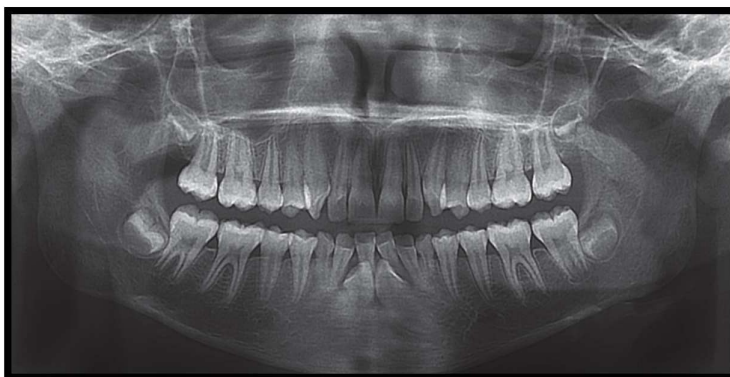


Fig 4: Type I subtype A. Both canines crosses midline and kissed each other.

Discussion

Mupparapu proposed classification of unilaterally mandibular canine transmigration depending on its path of deviation into five types. Type 1: Canine positioned mesioangularly across the midline, labial or lingual to anterior teeth, within the jaw bone (45.6%). Type 2: Canine horizontally impacted near the inferior border of the mandible inferior to apices of the incisors (20%). Type 3: Canine erupting either mesial or distal or on the contralateral side (14%). Type 4: Canine horizontally impacted near the inferior border of the mandible below the apices of posterior teeth on the opposite side (17%). Type 5: Canine positioned vertically in the midline (the long axis of the tooth crossing the midline) irrespective of eruption status (1.5%) (9). Mostly the transmigrated mandibular canines are asymptomatic, although follicular cyst formation and chronic infection have been reported. The exact mechanism and etiology of transmigration is still not clear (10). Over the years number of factors have been suggested by some authors as possible etiological factors are anomalous position of tooth germ, displacement of dental lamina in the embryonic life, agenesis of the adjacent teeth, strong eruption force, crowding, spacing, supernumerary teeth, excessive length of crown, premature loss of deciduous teeth, retention of canines, bony pathology resembling a cystic lesion, tumors, cysts, odontomas, fracture, genetic role and idiopathic causes (11-15). The anomaly is properly diagnosed by radiographic evaluation, which is primarily based on the panoramic radiograph.

The impacted mandibular canines which do not cross the midline, lie between 25 and 30 degree whereas which tend to

cross midline lies between 30 and 95 degree, which was observed by Howard whereas Thoma reported cases in which a radiolucent area resembling a cystic lesion surrounded the transmigrated canine

(16). However, it is very difficult to say whether these pathological conditions occurred after the migration of the canine or whether these pathological conditions were responsible for the transmigration

(17). Vichi et al proposed that increased axial inclination of the unerupted canine, proclination of the lower incisors, and an enlarged symphyseal cross-sectional area of the chin may be favourable conditions for transmigration (12). Qaradaghi had named it as "kissing canines" or "mirror image canines" which were defined as when there is migration of both canines at the same rate and on the same horizontal axis and parallel to each other may be meeting each other at the midline. Transmigration of the permanent canine is a rare dental anomaly (18). Clinicians should report more cases of this condition for better understanding of this rare anomaly. It is important to diagnose this condition at earlier stages of migration to prevent more complex problems.

References

1. Achint Garg, Suraj Agarwal, Shweta Agarwal, Samta Mittal, Parul Singh. Pattern Of Bilateral Transmigration Of Impacted Mandibular Canines: A Radiographic Study Of 3 Cases. J Evidence Based Med & Hlthcare, 2015; 2(7): 921-928.
2. Preema Melani Pinto, Vijay R Naik, Vikram Pai, Kalpana S Jadhav, Siddharth Revankar. Transmigration of Mandibular Canines - Clinical Implications. Ind J Dent Adv, 2015; 7(3): 212-216.

3. Nezar Watted, Emad Hussein, Obaida Awadi, Muhamad Abu-Hussein. Transmigration of Impacted Canines: A Report of Two Cases and a Review of the Literature. *Res Rev: J Dent Sci*, 2014; 2(4): 23-32.
4. Aydin U, Yilmaz H, Yildirim D. Incidence of canine impaction and transmigration in a patient population. *Dentomaxillofac Radiol*, 2004; 33: 164-169.
5. Aydin U, Yilmaz H. Transmigration of impacted canines. *Dentomaxillofac Radiol*, 2003; 32: 198-200.
6. Idris Faiq Qaradaghi. Bilateral transmigration of impacted mandibular canines: report of two cases and review. *Rev Clin Pesq Odontol*, 2010; 6(3): 271-275.
7. Auluck A, Nagpal A, Setty S, Pai K, Sunny J. Transmigration of impacted mandibular canines: report of four cases. *J Can Dent Assoc*, 2006; 72: 249-252.
8. Joshi, M.R.. Transmigrant Mandibular Canines: A Record of 28 Cases and a Retrospective Review of the Literature. *Angle Orthodont*, 2001; 71(1): 12-22.
9. Mupparapu M. Patterns of intraosseous transmigration and ectopic eruption of mandibular canines: review of literature and report of nine additional cases. *Dentomaxillofac Radiol*, 2002; 31(6): 355-360.
10. Alaejos-Algarra C, Berini-Ayres L, Gay-Escoda C. Transmigration of mandibular canines: report of six cases and review of the literature. *Quintessence Int*. 1998; 29: 395-398.
11. Nixon F, Lowey MN. Failed eruption of the permanent canine following open reduction of a mandibular fracture in a child. *Br Dent J*, 1990; 168: 204-205.
12. Vichi M, Franchi L. The transmigration of the permanent lower canine. *Minerva Stomatol*, 1991; 40: 579-589.
13. Fiedler LD, Alling CC. Malpositioned mandibular right canine: report of case. *J Oral Surg*, 1968; 26: 405-407.
14. Shapira Y, Mischler WA, Kufte MM. The displaced mandibular canine. *ASDC J Dent Child*, 1982; 49: 362-364.
15. Peck S. On the phenomenon of intraosseous migration of nonerupting teeth. *Am J Orthod Dentofacial Orthop*. 1998; 113: 515-517.
16. Howard R. The anomalous mandibular canine. *Br J Orthod*, 1976; 3 (2): 117-21.
17. Thoma KH. *Oral Surgery*. 2nd ed. St Louis, Miss: CV Mosby; 1952.
18. Idris Faiq Qaradaghi. Bilateral transmigration of impacted mandibular canines: report of two cases and review. *Rev Clin Pesq Odontol*, 2010; 6(3) Pattern Of Bilateral Transmigration Of Impacted Mandibular Canines: A Radiographic Study Of 3 Cases: 271-275.