

RESEARCH ARTICLE

NAM (NASOALVEOLAR MOULDING) VS NO NAM IN PATIENTS WITH UNILATERAL CLEFT LIP DEFORMITY

Dr. Siddhartha Chatterjee

Maxillofacial & Cleft reconstructive surgeon. Fellowship in Cleft & Craniofacial Surgery (Smile Train). Project Director (Rotary Cleft Foundation, Shree Jain Hospital & Research Center)

Corresponding Author: Dr. Siddhartha Chatterjee. E mail: scmaxfac@hotmail.com.

ABSTRACT

Pre-surgical infant orthopedics has been employed since 1950 as an adjunctive neonatal therapy for the correction of cleft lip and palate. Most of these therapies did not address deformity of the nasal cartilage in unilateral and bilateral cleft lip and palate as well as the deficiency of the columella tissue in infants with bilateral cleft. The nasolaveolar molding (NAM) technique, a new approach to pre-surgical infant orthopaedics developed by Grayson, reduces the severity of the initial cleft alveolar and nasal deformity. This enables the surgeon and the patient to enjoy the benefits associated with repair of a cleft deformity that is minimal in severity. Long term studies on NAM therapy indicate better lip and nasal form, reduced oronasal fistula and labial deformities, 60% reduction in the need for secondary alveolar bone grafting. No effect on growth of midface in sagittal and vertical plane has been recorded up to the age of 18 years. With proper training and clinical skills NAM has demonstrated tremendous benefit to the cleft patients as well as to the surgeon performing the repair. This paper will discuss and show results in the group of patients who opted for NAM and who did not. (2017, Vol. 01; Issue 01: Page 16 - 22)

Keywords: Cleft lip, Nasolaveolar molding, NAM.

WHAT IS NAM

Nasoalveolar moulding (NAM) is an orthopaedic technique where moulding of the nose and the alve-

olus is done using mainly removable passive devices. It is commonly used in wider and more extensive clefts which have significant nasolabial deformity.

Nasoalveolar moulding technique is used to direct growth of alveolar ridge, lips and nose in the pre-surgical treatment of cleft lip and palate (1, 2).

EVOLUTION

Pre-surgical infant orthopaedics has been used in the treatment of cleft lip and palate patients for centuries. The early techniques were focused on elastic retraction of the protruding premaxilla followed by stabilization after surgical repair. In 1689, Hoffmann demonstrated the use of facial binding to narrow the cleft and prevent postsurgical dehiscence. A similar technique was shown by Desault in 1790 to retract the maxilla before surgical repair in patients with bilateral cleft repair. In 1844, Hullihen stressed the importance of presurgical preparation of clefts using an adhesive tape binding. Esmarch and Kowalzig used a bonnet and strapping to stabilize the premaxilla after surgical retraction. In 1927, Brophy demonstrated the passing of a silver wire through both the ends of the cleft alveolus and then progressively tightened the wire to approximate the ends of the alveolus before lip repair (1).

The modern school of presurgical orthopaedic treatment in cleft lip and palate was started by McNeil in 1950. He used a series of plates to actively mould the alveolar segments into the desired position. Burston, an orthodontist, further developed McNeil's technique and made it popular. In 1975, Georgiade and Latham introduced a pin-retained active appliance to simultaneously retract the premaxilla and expand the posterior segments over a period of several days. Hotz

in 1987 described the use of a passive orthopaedic plate to slowly align the cleft segments (3).

In 1993, Grayson et al. described a new technique to pre-surgically mould the alveolus, lip and nose in infants born with cleft lip and palate. The original research on neonatal moulding of the nasal cartilage was performed by Matsuo using silicone tubes to mould the nostril. The nasoalveolar moulding appliance (NAM) consists of an intraoral moulding plate with nasal stents to mould the alveolar ridge and nasal cartilage concurrently. The objective of the pre-surgical NAM is to reduce the severity of the original cleft deformity and thereby enable the surgeon to achieve better repair of the alveolus, lip and nose. Use of the NAM technique has also eliminated surgical columella reconstruction and the resultant scar tissue in bilateral cleft lip and palate. The nasoalveolar moulding technique has been shown to significantly improve the surgical outcome of the primary repair in cleft lip and palate patients compared to other techniques of pre-surgical orthopaedics (1, 2).

CONCEPT OF NAM

NAM has evolved over the past decade into its present form through contributions made by clinicians and parents. The alignment of alveolar segment creates the foundation upon which excellent results of lip and primary nasal surgery are dependent. Challenges for a surgeon is the creation of a tension free closure of cleft lip and aesthetically acceptable nose and columella. Repair of nose and lip after NAM tends to heal under minimal tension, thereby reducing the scar formation

and improving aesthetic results (1, 4).

Inclusion criteria

Infants reporting to the hospital with complete unilateral cleft lip and palate deformity before 2 months of age

Exclusion Criteria

- Patients with any syndrome (Down's, Apert, Treacher Collin etc)
- Patients with cleft lip and palate reporting after 2 months of age
- Babies with uncooperative parents
- Bilateral defects were not included in the study

METHODOLOGY

- Patients who opted for NAM were considered as early as 6 days of birth.
- According to Greyson, the birth estrogen levels are very much higher than normal value, which has a synergistic effect on cartilage mouding.
- Patients reporting later than 2 months of age were not considered.
- Initial impression of the cleft lip and palate infant is obtained within the first week of birth. A heavy-bodied silicone impression material is used to take the initial impression. The impression can be taken in a clinical setting that is prepared to handle airway emergency, if at all encountered. A surgeon is always present during the impression process. The infant is held upside down by the surgeon and the impression tray is inserted into the oral cavity. The infant is held in an inverted position to prevent the

tongue from falling back and to allow fluids to drain out of the oral cavity. The tray is seated until the impression material adequately covers the anatomy of the upper gum pads. Once the impression material is set, the tray is removed and the mouth is examined for residual impression material. The impression is then poured with dental stone to obtain an accurate cast

- A denture base is made with cold cure acrylic and stents with a hole in the plate.
- The specialized denture plate is then adapted to patient's (infants) mouth and fitted with denture adhesive and Steristrips
- The plate with stent is activated on every 14th day
- Again impression is made to check the progress and study parameter recording (1, 2, 5)
- Out of 49 patients selected for study, 25 patients opted for NAM and 24 patients were kept in the control group in whom NAM was not applied.

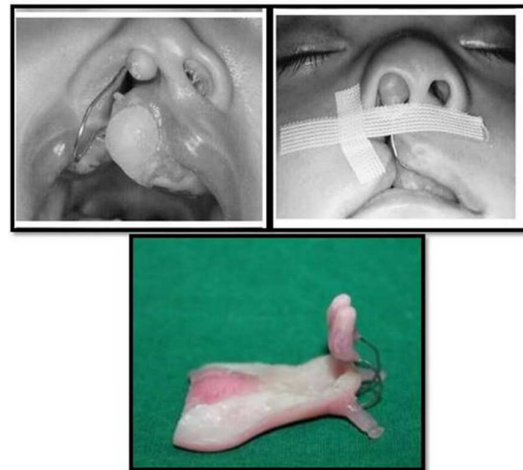


Fig 1: NAM appliance

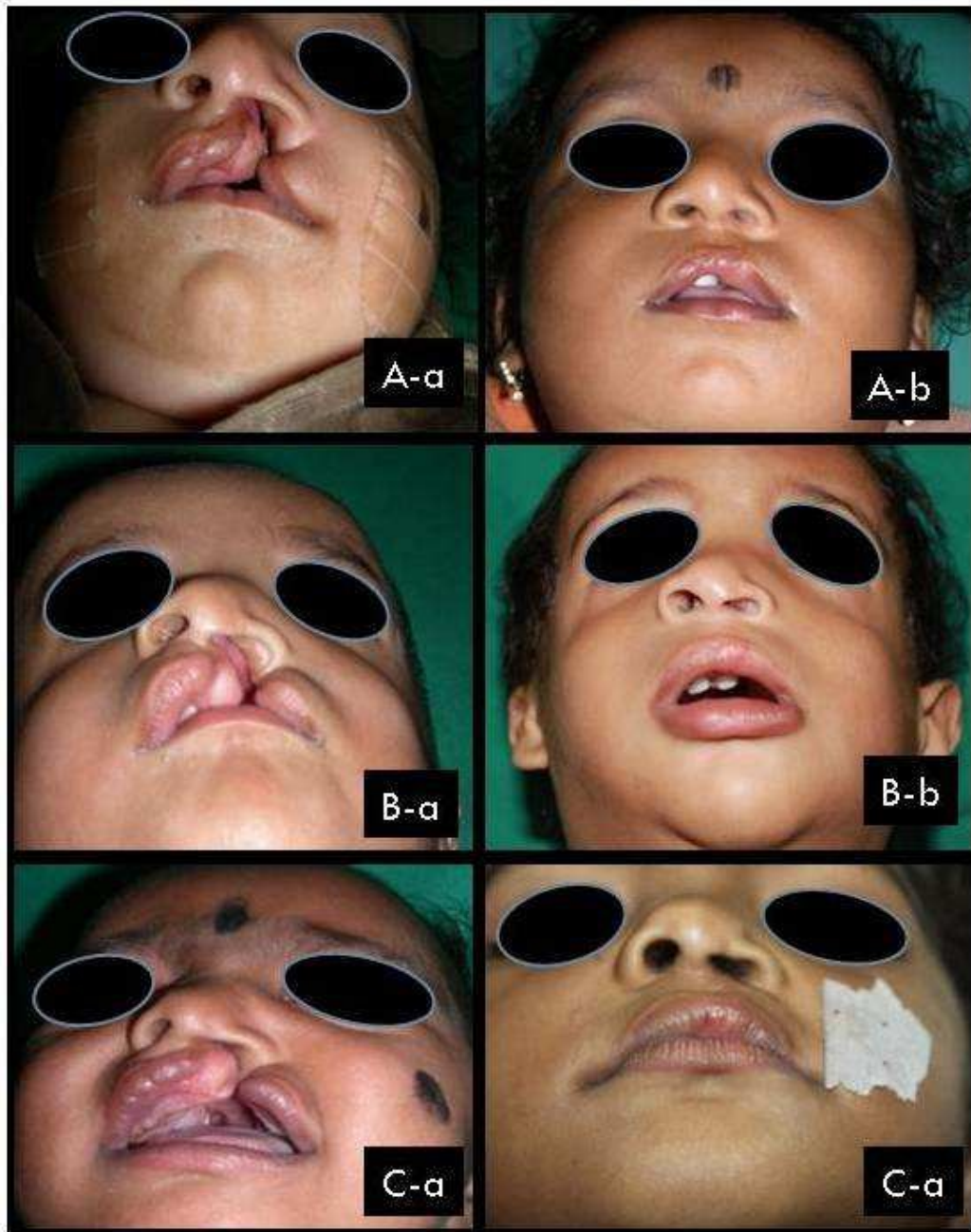

Fig 2: Patients who opted for NAM [A-a, B-a, C-a: Before, A-b, B-b, C-b: After]

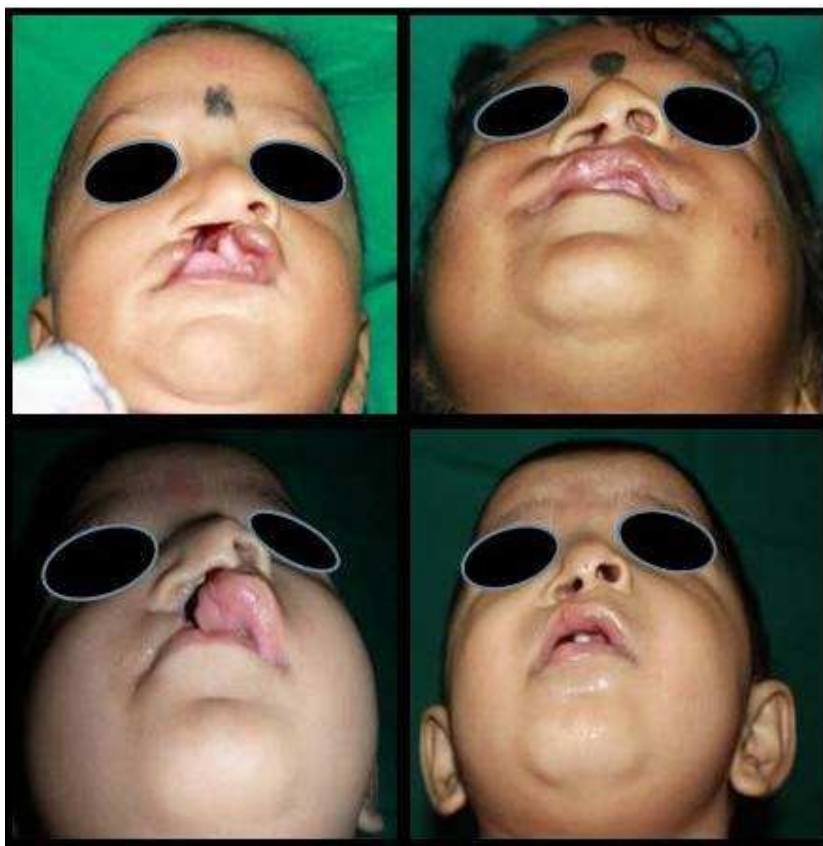

Fig 3: Patients who did not opt for NAM

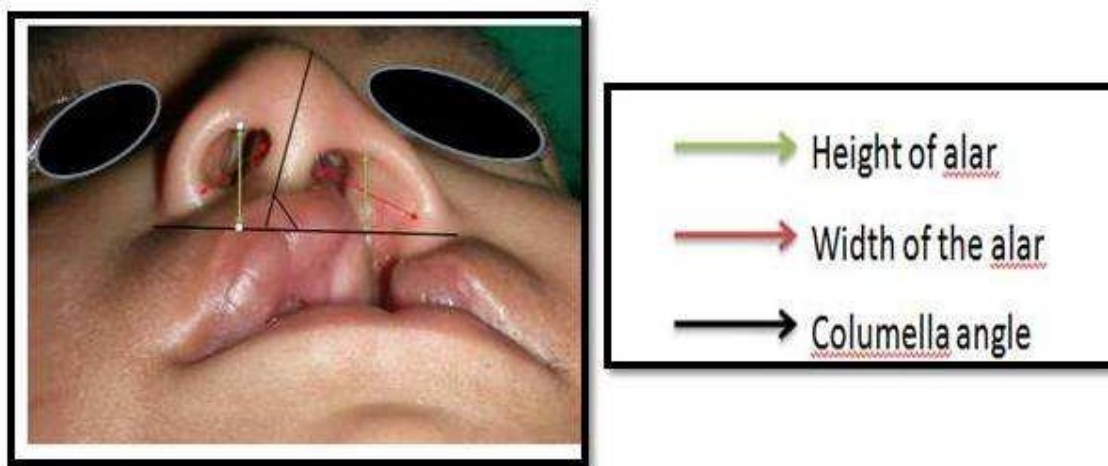
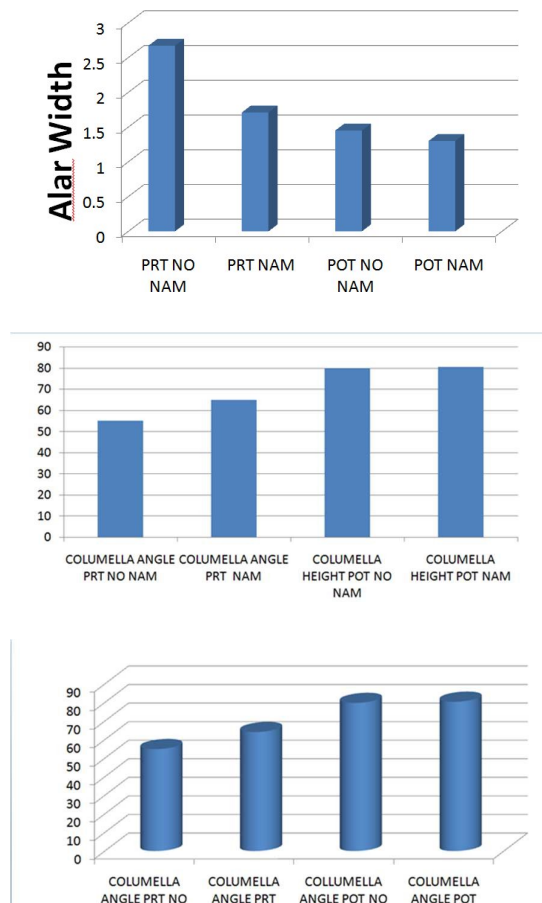


Fig 4: Parameters measured

RESULTS

We studied 49 patients with unilateral cleft deformity. We found that there was a comparatively greater reduction in alar width, alar height and columella angle in NAM patients compared to no NAM patients.

NAM Vs NO-NAM



DISCUSSION

The NAM appliance helps to align the tissues before the primary lip and nose repair, thus enabling the surgeon to achieve a better and more predictable outcome with less scar tissue formation. Major surgical closure of the lip and nose are performed between 3-5 months of age. As the alveolar segments are in

near approximation because of NAM, surgical correction is simple to perform. The incorporation of nasal stent is done when the alveolar gap width is decreased to 5 mm. It is fabricated from 0.036 gauge round wire and resembles kidney shape. The only problem associated with NAM with patient/baby compliance. Multiple visits to hospital to activate the appliance is also quite bothersome, but it also held true for vaccinations. The parents should be trained adequate to maintain a baby with NAM plate. They should be aware of the possible complications and immediate remedy. Fractured NAM plates should never be used in the baby's mouth. Cheek rashes with the tape adhesive are a common problem. Denture adhesive used to maintain the plate in position should be used proportionately. Excess should not tickle down the throat to develop problem like aspiration, stomach upsets etc. Having all these, we should always measure the problem vs risk ratio and opt for the better treatment. (1,6, 7).

BENEFITS OF NAM

- Change in nasal shape is stable with less scar tissue
- Reduces surgical revisions for excessive scar tissue of nasal and labial deformities
- Teeth have a better chance of erupting in good position with good periodontal support
- MOST patients do not require a secondary bone graft (6)

COMPLICATIONS

The most common problems observed during NAM therapy are irritation to the oral mucosa, gingival tissue or nasal mucosa. Ulceration

from excessive pressure applied by the appliance is commonly found in the oral vestibule and on the labial side of the premaxilla. Examination should be done on each visit for ulceration and adjustments should be made to the moulding plate to relieve sore spots. The intra nasal tip can become inflamed if too much force is applied by the upper lobe of the nasal stent. If the band is too tight, the skin under the horizontal prolabium band can become ulcerated. Another area of tissue irritation is the cheeks. Extreme care should be taken while removing the cheek tape to avoid any irritation to the skin. Skin barrier tapes like Tegaderm™ are recommended. Slight relocation of the position of the tape during treatment is also recommended to provide rest to the tissues in case they become irritated. It is also recommended that an al-oevera gel to be applied to the cheeks when changing (6, 7).

Conclusion

NAM technique has been shown to improve the surgical outcome of cleft lip patients compared with other techniques of pre-surgical orthopedics. NAM has proved itself effective and simple adjunctive therapy for approximating hard and soft tissue cleft deformity before surgery. However, the members of the cleft lip and palate team should provide the parents and caregivers adequate training, education, active support and encouragement during NAM treatment. Lack of parent's compliance and commitment

may result in less than ideal clinical outcome.

REFERENCES

1. Barry H Grayson, D Maull . Nasoalveolar molding for infants born with clefts of the lip, alveolus, and palate. Clin Plastic Surg, 2004; 31: 149-158.
2. Barry H Grayson, Pedro E Santiago, Lawrence E Brecht, Court B Cutting. Presurgical Nasoalveolar Molding in Infants with Cleft Lip and Palate. Cleft Palate-Craniofacial Journal, 1999; 36(6): 486-498.
3. Akshai Shetty KR, Krishna-murthy B, Dharma RM, Viswapurna PS. Presurgical Nasoalveolar Molding in Patients with Unilateral Clefts of Lip, Alveolus and Palate –A case report. Annals and Essences of Dentistry, 2011; 3(2): 50-52.
4. Samuel Berkowitz. Cleft Lip and Palate: Diagnosis and Management. 3rd Edition. Springer.
5. Jin-Sun Kim, Young-Jin Kim, Soon-Hyeun Nam, Hyun-Jung Kim. Effect of presurgical nasoalveolar molding in unilateral cleft lip and palate infants. J Korean Acad Pediatr Dent, 2013; 40(3): 209-214.
6. Suri S. Optimal timing for nasal cartilage molding in presurgical nasoalveolar molding. Plast Reconstr Surg., 2010; 125(3): 112e-113e.
7. Aizenbud D, Ronen J. Facial casts (moulage) of infants with cleft defects during nasoalveolar molding. J Oral Maxillofac Surg, 2011; 69(3): 935-938.